


Evaluating ED Patients Who Present with AMS & Coma: A Systematic Approach

Edward P. Sloan, MD, MPH



FERNE Brain Illness and Injury Course

Edward P. Sloan, MD, MPH



**4th Mediterranean Emergency Medicine Congress
Sorrento, Italy September 17, 2007**

Edward P. Sloan, MD, MPH



Edward Sloan, MD, MPH

Professor

**Department of Emergency Medicine
University of Illinois College of Medicine
Chicago, IL**

Edward P. Sloan, MD, MPH



**Attending Physician
Emergency Medicine**

**University of Illinois Hospital
Our Lady of the Resurrection Hospital**

Chicago, IL

Edward P. Sloan, MD, MPH



Disclosures

- No advisory boards
- No speakers' bureaus
- FERNE Executive Board
- FERNE grants from industry
- ACEP Clinical Policy and Scientific Review Committees

Edward P. Sloan, MD, MPH



Global Objectives

- Improve coma pt outcome
- Know how to quickly evaluate coma risk
- Determine how to use empiric meds
- Provide rationale for ED neuroimaging
- Facilitate disposition, improve pt outcome
- Improve Emergency Medicine practice

Edward P. Sloan, MD, MPH



Session Objectives

- Present a relevant patient case
- Discuss key clinical questions
- State key learning points
- Review the coma evaluation procedure
- Discuss the procedure of empiric meds
- Evaluate the patient outcome and ED documentation

Edward P. Sloan, MD, MPH



A Clinical Case

Edward P. Sloan, MD, MPH



EMS Presentation

- 54 year old EMS call for “found down”
- Pt in street
- Possible seizure
- Unresponsive
- Glucose normal
- No other history available

Edward P. Sloan, MD, MPH



ED Presentation

- Pt unresponsive
- Vitals: BP 220/110 HR 110 RR 16
- Afebrile
- No trauma
- Normal cardiopulmonary, abdomen
- Minimal twitching of R face noted

Edward P. Sloan, MD, MPH



Key Clinical Questions

- How to evaluate this unresponsive pt?
- What is the differential diagnoses?
- What are the etiologies of coma?
- What tests must be performed?
- What neuroimaging to be obtained?
- What therapies must be provided?

Edward P. Sloan, MD, MPH



AMS & Coma: Key Concepts

Edward P. Sloan, MD, MPH



Stupor & Lethargy

- Stupor definition:
 - A state of reduced or suspended sensibility, a daze
 - Decreased responsiveness
 - Similar to lethargy
- Reduced GCS, but above 8

Edward P. Sloan, MD, MPH



Acute Delirium

- Delirium definition:
 - Mental confusion
 - Clouded consciousness
 - Disorientation, hallucinations
 - Delusions, anxiety
 - Incoherent speech
- GCS generally above 8

Edward P. Sloan, MD, MPH



Coma

- Coma definition:
 - Extreme alteration in mental status
 - Unresponsive
 - Similar to being unconscious
- Markedly low GCS, 8 or less

Edward P. Sloan, MD, MPH



Coma Pathophysiology

- Bilateral cerebral cortex dysfunction
 - Toxic/metabolic
 - Mass lesion, increased ICP
 - Cerebral ischemia, infarct
- Brainstem suppression of reticular activating system (RAS)
 - Ischemia, infarct

Edward P. Sloan, MD, MPH



Coma Etiologies

- Hypoperfusion/ischemia
- Toxic/metabolic
- Increased ICP
 - Chronic space-occupying lesion
 - Acute hemorrhage
- Infection
- Seizure
- Psychogenic fugue state

Edward P. Sloan, MD, MPH



Coma Etiologies

- T trauma, temperature
- I infections
- P psychiatric, porphyria
- S space-occupying lesion, stroke, SAH

Edward P. Sloan, MD, MPH



Coma Etiologies

- A alcohol, other toxins
- E endocrine
- I insulin (DM complications)
- O oxygen deficiency, opiates
- U uremia, renal disorders

Edward P. Sloan, MD, MPH



Coma Pt Treatment Priorities

- Assess ABCs, vitals
- Provide empiric therapies
- Assess for signs of likely etiology
 - Trauma, toxic, infection, ischemia, tumor
- Conduct a systematic neurological exam
- Obtain neuroimaging
- Consider EEG monitoring

Edward P. Sloan, MD, MPH



A Perspective on Procedures

- Critically ill ED patients
- Coma is a true medical emergency
- Limited time and resources
- A need to diagnose and act
- “Emergency physicians take a surgeon’s approach to medical emergencies.”
- We do procedures

Edward P. Sloan, MD, MPH



Empiric Therapies: *The Procedure*

Edward P. Sloan, MD, MPH



Empiric Therapies: Principles

- Airway management:
 - Nasal or oral airway, ventilate, prepare for RSI
- Oxygen therapy
- Obtain an accucheck, administer glucose
- Fluid bolus for hypotension
- Naloxone if evidence of narcotic use/abuse
- Judicious flumazenil use for benzo abuse
- Thiamine in alcohol abuse

Edward P. Sloan, MD, MPH



Empiric Therapy

- Control the airway, ventilate

Edward P. Sloan, MD, MPH



Empiric Therapy

- Control the airway, ventilate
- Do a bedside glucose determination
 - Provide D50 for hypoglycemia
 - Avoid hyperglycemia

Edward P. Sloan, MD, MPH



Empiric Therapy

- Control the airway, ventilate
- Do a bedside glucose determination
 - Provide D50 for hypoglycemia
 - Avoid hyperglycemia
- Detect hypoperfusion (Decreased CPP)
 - CPP = MAP – ICP (MAP > 90 mmHg key)
 - NS fluid boluses up to 500 cc each

Edward P. Sloan, MD, MPH



Empiric Therapy

- Assess for narcotic overdose
 - Nalaxone 2 mg IV or sublingual
 - Be prepared to restrain patient

Edward P. Sloan, MD, MPH



Empiric Therapy

- Assess for narcotic overdose
 - Nalaxone 2 mg IV or sublingual
 - Be prepared to restrain patient
- Assess for benzodiazepine overdose
 - Flumazenil 0.2 mg IVP x 5 (max dose 1 mg)
 - If acute ingestion, initial dose OK, no seizure

Edward P. Sloan, MD, MPH



Empiric Therapy

- Assess for narcotic overdose
 - Nalaxone 2 mg IV or sublingual
 - Be prepared to restrain patient
- Assess for benzodiazepine overdose
 - Flumazenil 0.2 mg IVP x 5 (max dose 1 mg)
 - If acute ingestion, initial dose OK, no seizure
- Examine for likely EtOH abuse
 - Thiamine 100 mg IVP or to IVF

Edward P. Sloan, MD, MPH



Coma Patient Evaluation: *The Procedure*

Edward P. Sloan, MD, MPH



Coma Exam: Principles

- Many etiologies are apparent on exam
- Step-wise approach allows for detection
- Follows empiric therapies
- Precedes, directs neuroimaging
- Establishes baseline
- Mental status change then detectable

Edward P. Sloan, MD, MPH



Coma Evaluation Procedure

- Assess the pt's overall mental status

Edward P. Sloan, MD, MPH



Coma Evaluation Procedure

- Assess the pt's overall mental status
- Assess the ABCs (trauma)
 - Airway & gag reflex
 - Breathing pattern and sufficiency
 - Circulation adequacy and hypotension

Edward P. Sloan, MD, MPH



Coma Evaluation Procedure

- Assess the pt's overall mental status
- Assess the ABCs (trauma)
 - Airway & gag reflex
 - Breathing pattern and sufficiency
 - Circulation adequacy and hypotension
- Assess the skin, breath (toxidromes)

Edward P. Sloan, MD, MPH



Coma Evaluation Procedure

- Assess the pt's overall mental status
- Assess the ABCs
 - Airway & gag reflex
 - Breathing pattern and sufficiency
 - Circulation adequacy and hypotension
- Assess the skin, breath (toxidromes)
- Detect posturing following stimulation

Edward P. Sloan, MD, MPH

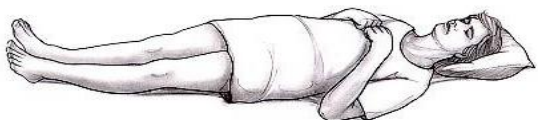

Decorticate posturing in comatose patient

Lesion above the red nucleus

Lower limbs extend, upper limbs flex following stimulus

Activity in the brainstem flexor center, the red nucleus



B. Decorticate : upper limbs flex, lower limbs extend

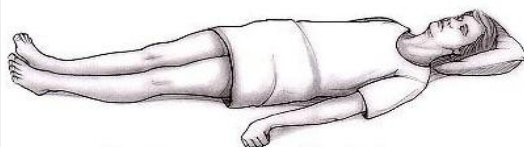


Decerebrate posturing in comatose patient

Upper and lower limbs extend following stimulus (pain, startle, or auditory)

Normal inhibition by cortex on the extensor facilitation part of retic form is missing, so extensors hyperactive

Lat vest nuclei involved, ablate and extensor posturing reduced



A. Decerebrate : upper and lower limbs extend



Clinical Value of Decorticate/Decerebrate Signs

Decorticate posturing indicates a higher level of brainstem injury than decerebrate posturing (a good thing), so

Comatose patients who go from decerebrate to decorticate (ascending progression of impaired area) have a better prognosis than those that go from decorticate to decerebrate (descending progression of impaired area).

Descending impairment will be fatal if medullary respiratory and cardiovascular centers are damaged



Coma Evaluation Procedure

- Calculate the Glasgow Coma Scale score
 - Eye Opening (4), Verbal (5), Motor (6)
 - 13-15 Mild AMS, 4-8 Coma, 3 Vegetative

Edward P. Sloan, MD, MPH



Coma Evaluation Procedure

- Calculate the Glasgow Coma Scale score
 - Eye Opening (4), Verbal (5), Motor (6)
 - 13-15 Mild AMS, 4-8 Coma, 3 Vegetative
- Detect abnormal reflexes
 - Corneal reflex
 - Babinski (Chaddock)

Edward P. Sloan, MD, MPH



Coma Evaluation Procedure

- Examine the pupils
 - Size and equality
 - Light reactivity, consensual response

Edward P. Sloan, MD, MPH



Coma Evaluation Procedure

- Examine the pupils
 - Size and equality
 - Light reactivity, consensual response
- Perform the Doll's eye maneuver

Edward P. Sloan, MD, MPH



Doll's Eye Maneuver

- Oculocephalic reflex
- Caution with suspected c-spine injury
- Eyes should continue to face to ceiling
- If eyes follow movement of head to side, suspect brainstem involvement in coma

Edward P. Sloan, MD, MPH



Coma Evaluation Procedure

- Examine the pupils
 - Equality
 - Light reactivity
- Perform the Doll's eye maneuver
- Detect evidence of psychogenic coma
 - Protective reflex
 - Propriety reflex

Edward P. Sloan, MD, MPH



Coma Evaluation Procedure

- Look for ongoing seizure activity

Edward P. Sloan, MD, MPH



Coma Evaluation Procedure

- Look for ongoing seizure activity
- Perform cold calorics

Edward P. Sloan, MD, MPH



Cold Caloric Examination

- Oculovestibular reflex
- Normal for slow movement of eyes towards, fast movement away from cold water into ear canal
- If eyes move towards cold water, intact brainstem despite coma
- If no eye movement towards stimulation, suspect brainstem injury

Edward P. Sloan, MD, MPH



Coma Evaluation Procedure

- Look for ongoing seizure activity
- Perform cold calorics
- Document checklist of coma findings
 - Presence of coma, responsiveness, GCS
 - Vital signs, ABCs, empiric therapies
 - Exam findings checklist
 - Likely etiology
 - Likely location of lesion

Edward P. Sloan, MD, MPH



ED Documentation & Patient Outcome

Edward P. Sloan, MD, MPH



ED Coma Documentation

- Pt unresponsive to all stimuli cw coma
- Airway adequately controlled
 - Decreased gag reflex
 - OK Airway with nasopharyngeal airway
- Adequate ventilation, pO₂ OK 100% NRB
- Hypertension noted, tachycardia
 - Labetalol 20 mg IVP
 - Repeat BP OK

Edward P. Sloan, MD, MPH



ED Coma Documentation

- No pallor, cyanosis, or cherry red skin
- No abnormal breath or EtOH
- Adequate ventilation, pO₂ OK 100% NRB
- Hypertension noted, tachycardia
 - Labetalol 20 mg IVP
 - Repeat BP OK
- No pathologic posturing to stimulation
- Estimated GCS = 3

Edward P. Sloan, MD, MPH



ED Coma Documentation

- Corneal reflex intact, no upgoing toes bilat
- Pupils midrange, equal, reactive
- Fixed gaze to R, no Doll's eyes noted
- Protective reflex to arm dropping absent
- No propriety reflex noted
- Facial twitching noted on R, likely SE
- Cold calorics not indicated

Edward P. Sloan, MD, MPH



ED Coma Documentation

- Coma
- Likely etiology subtle status epilepticus
- No toxidrome or intoxication
- Non-focal exam, mass lesion not likely
- No evidence psychogenic seizure
- CT negative, tox screen negative
- Lorazepam, fosphenytoin
- EEG negative in ED

Edward P. Sloan, MD, MPH



Patient Outcome

- Hx SE, compliant with meds?
- Hx carotid occlusion
- Due to have carotid endarterectomy
- Pt remained unresponsive after EEG
- Admitted for ongoing observation
- Expedited surgery anticipated

Edward P. Sloan, MD, MPH



ED Comatose Patient Exam: *A Retrospective*

Edward P. Sloan, MD, MPH



ED Comatose Patient Exam

- Address the ABCs
- Quickly assess for coma etiologies
- Perform a systematic neuro exam
- Expedited neuroimaging, consultation
- Documentation of coma checklist
- Definitive care plan established in ED
- Optimized coma patient outcome

Edward P. Sloan, MD, MPH



Questions??

www.ferne.org
ferne@ferne.org

Edward Sloan, MD, MPH
edsloan@uic.edu
312 413 7490

ferne_memc_2007_braincourse_sloan_coma_091707_finalcd.ppt
7/27/2008 4:35 PM

Edward P. Sloan, MD, MPH

