

**FERNE / EMRA 2007 Acute Ischemic Stroke Patients :
What Must We Be Able to Do in order to Provide tPA
in the ED (Mimickers, Stroke Scales, and CT Interpretation)?
Edward P. Sloan, MD, MPH, FACEP**

ED Stroke Patient Management:

What must we be able to do in order to provide tPA in the ED? (mimics, stroke scales, timing, and CT interpretation)?

J. Stephen Huff, MD



EMRA /FERNE

**Case Conference:
The ED Management of
Acute Ischemic Stroke
Patients**

J. Stephen Huff, MD



2008 SAEM Annual Meeting

**Washington, DC
May 31, 2008**

J. Stephen Huff, MD



J. Stephen Huff, MD

Associate Professor

*Department of Emergency Medicine
University of Virginia
Charlottesville, Virginia*

J. Stephen Huff, MD



Disclosures

- Executive Board, Foundation for Education and Research in Neurologic Emergencies
- No individual financial disclosures

J. Stephen Huff, MD



www.ferne.org

J. Stephen Huff, MD



**FERNE / EMRA 2007 Acute Ischemic Stroke Patients :
What Must We Be Able to Do in order to Provide tPA
in the ED (Mimickers, Stroke Scales, and CT Interpretation)?
Edward P. Sloan, MD, MPH, FACEP**

Key Clinical Questions

- You are obliged to be able to give tPA...
- What diagnostic skills?
- What use of stroke scales?
- What CT interpretation skills?
- What IV tPA use skills?

J. Stephen Huff, MD



Diagnostic Skills

- Identify a stroke
- Start with the Cincinnati stroke scale
- Identify speech and language deficit
- Identify hemiparesis
- Identify cranial nerve deficits c/w stroke
- Consider mental status changes

J. Stephen Huff, MD



Diagnostic Skills

- Exclude toxic / metabolic causes
- Exclude seizure syndromes
- Exclude TIAs
- Is the deficit significantly improving during the time that you are preparing to give IV tPA?

J. Stephen Huff, MD



Stroke Scales Use

- Estimate the severity of the stroke
- Know what patients were treated in the NINDS clinical trials
- Be able to identify significant or moderate stroke

J. Stephen Huff, MD



Cincinnati Scale

- Face
- Arm
- Speech

J. Stephen Huff, MD



NIHSS: LOC

- LOC overall 0-3 pts
- LOC questions 0-2 pts
- LOC commands 0-2 pts

- LOC: 7 points total

J. Stephen Huff, MD



**FERNE / EMRA 2007 Acute Ischemic Stroke Patients :
What Must We Be Able to Do in order to Provide tPA
in the ED (Mimickers, Stroke Scales, and CT Interpretation)?
Edward P. Sloan, MD, MPH, FACEP**

NIHSS: Cranial Nerves

- Gaze palsy 0-2 pts
- Visual field deficit 0-3 pts
- Facial motor 0-3 pts

- Gaze/Vision/
Cranial nerves: 8 points total

J. Stephen Huff, MD



NIHSS: Motor

- Each arm 0-4 pts
- Each leg 0-4 pts

- Motor: 8 points total
(8 right, 8 left)

J. Stephen Huff, MD



NIHSS: Cerebellar

- Limb ataxia 0-2 pts

- Cerebellar:
total 2 points

J. Stephen Huff, MD



NIHSS: Sensory

- Pain, noxious stimuli 0-2 pts

- Sensory: 2 points total

J. Stephen Huff, MD



NIHSS: Language

- Aphasia 0-3 pts
- Dysarthria 0-2 pts

- Language: 5 points total

J. Stephen Huff, MD



NIHSS: Inattention

- Inattention 0-2 pts

- Inattention:
total 2 points

J. Stephen Huff, MD



**FERNE / EMRA 2007 Acute Ischemic Stroke Patients :
 What Must We Be Able to Do in order to Provide tPA
 in the ED (Mimickers, Stroke Scales, and CT Interpretation)?
 Edward P. Sloan, MD, MPH, FACEP**

NIHSS Composite

- CN (visual): 8
- Unilateral motor: 8
- LOC: 7
- Language: 5
- Ataxia: 2
- Sensory: 2
- Inattention: 2

J. Stephen Huff, MD



Four Main NIHSS Areas

- CN/Visual: Facial palsy, gaze palsy, visual field deficit
- Unilateral motor: Hemiparesis
- LOC: Depressed LOC, poorly responsive
- Language: Aphasia, dysarthria, neglect
- 28 total points

J. Stephen Huff, MD



NIHSS ED Estimate

- CN (visual): 8
- Unilateral motor: 8
- LOC: 8
- Language/Neglect: 8
- Mild: 2, Moderate: 4, Severe: 8
- +/- Incorporates other elements

J. Stephen Huff, MD



NIHSS Patient Estimate

- CN/Visual: R vision loss, no fixed gaze 4
- Unilateral motor: hemiparesis 8
- LOC: mild decreased LOC 2
- Language: speech deficit, neglect 4
- Approx 18 points total
- Moderate to severe stroke range

J. Stephen Huff, MD



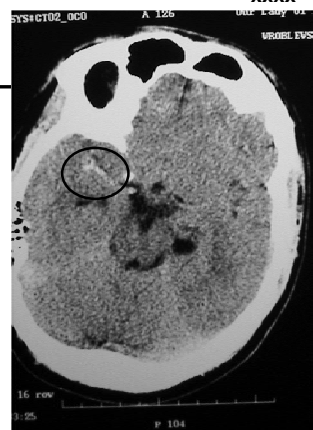
CT Interpretation Skills

- No insular ribbon or MCA sign
- No detailed assessment
- Identify asymmetry and edema
- Identify blood, mass lesion
- Identify any area of hypodensity c/w a recent stroke of many hours duration that precludes IV tPA use

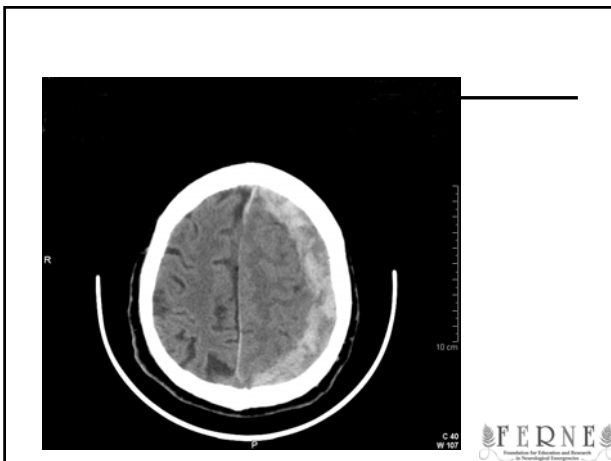
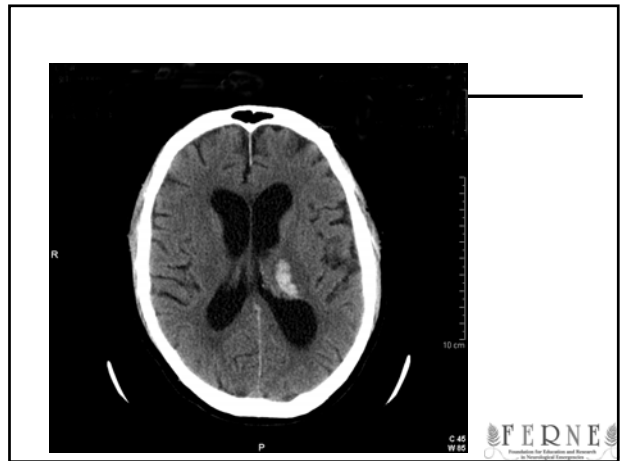
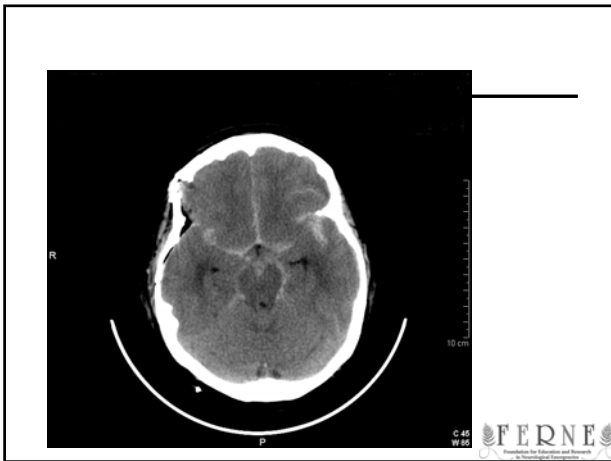
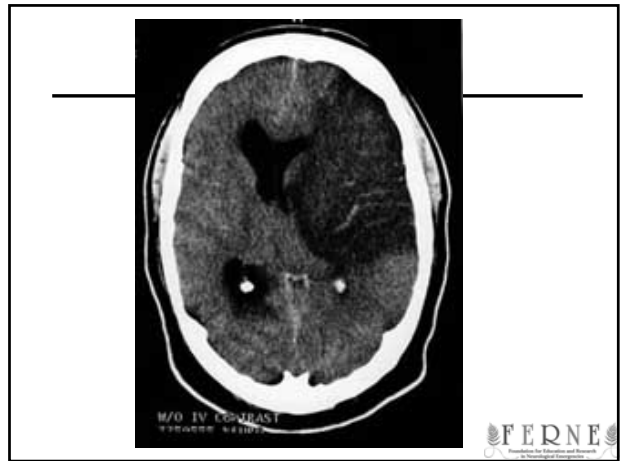
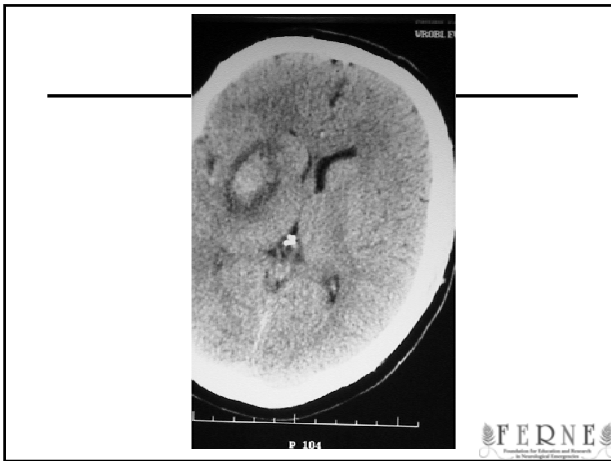
J. Stephen Huff, MD



Hyperdense
MCA Sign




**FERNE / EMRA 2007 Acute Ischemic Stroke Patients :
What Must We Be Able to Do in order to Provide tPA
in the ED (Mimickers, Stroke Scales, and CT Interpretation)?
Edward P. Sloan, MD, MPH, FACEP**



Timing...

J. Stephen Huff, MD



**FERNE / EMRA 2007 Acute Ischemic Stroke Patients :
What Must We Be Able to Do in order to Provide tPA
in the ED (Mimickers, Stroke Scales, and CT Interpretation)?
Edward P. Sloan, MD, MPH, FACEP**

Timing...

Time of onset must be clear

J. Stephen Huff, MD



IV tPA Use Skills

- Identify indications, contraindications
- Quickly get the tests and consults
- Communicate with the neurologist
- Obtain consent with family and know what statistics are relevant
- Document the interaction
- Maintain BP below 185/110 range
- Follow the NINDS protocol closely

J. Stephen Huff, MD



ED tPA Documentation

- With tPA, there is a 30% greater chance of a good outcome at 3 months
- With tPA use, there is 10x greater risk of a symptomatic ICH
- Mortality rates at 3 months are the same regardless of whether tPA is used

J. Stephen Huff, MD



ED tPA Documentation

- What was the rationale, risk/benefit assessment for using or not using tPA?
- What was done to expedite treatment, consult neurology and radiology?

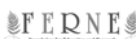J. Stephen Huff, MD



Conclusions

- The IV tPA skill set is identified, limited, and manageable
- It is possible to provide quality emergency services with IV tPA
- Identify good patient candidates
- Make it happen quickly
- Document the ED management

J. Stephen Huff, MD



Questions?

www.FERNE.org

huff@virginia.edu

ferne_emra_2008_neuro_conf_saem_huff_tpskills_052308

J. Stephen Huff, MD

